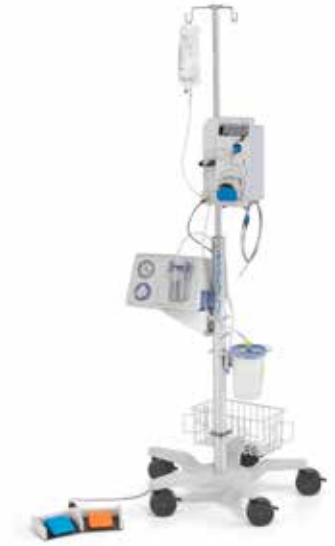
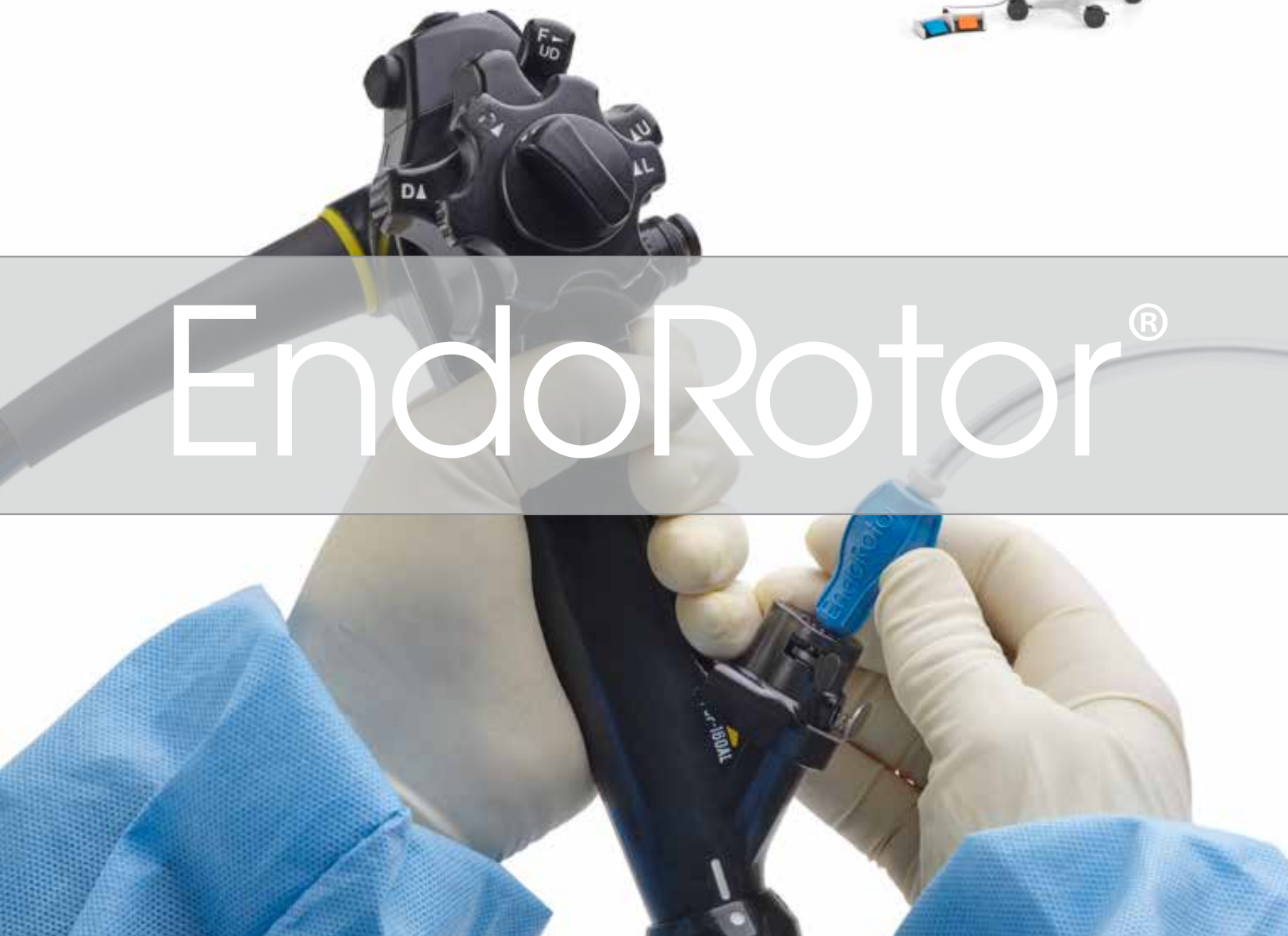
- Abstract Summaries
- Case Reports



EndoRotor®

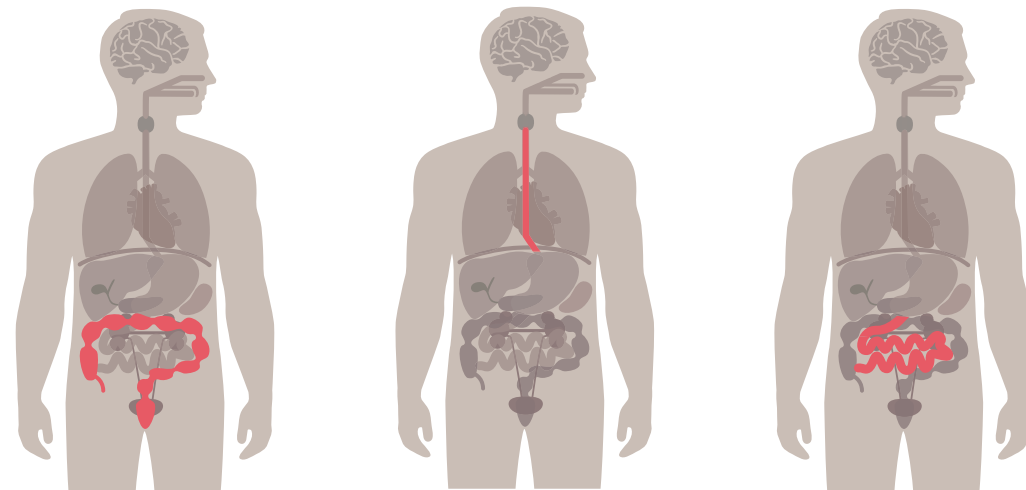


EndoRotor EPR™



Safety and efficacy of a novel powered endoscopic debridement tissue resection device for management of difficult colon and foregut lesions: first multicenter U.S. experience¹

Kaul et al. Published in GIE, 2020



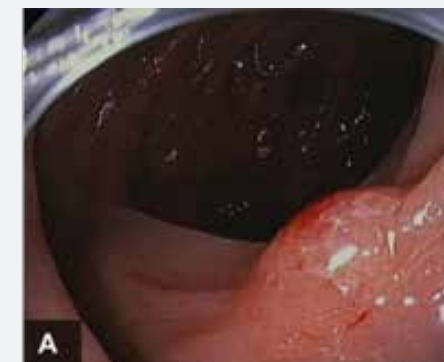Objective: The EndoRotor®, nonthermal, powered endoscopic debridement (PED) instrument is a novel device used in the GI tract. It uses adjustable suction and a rotary cutting blade to precisely resect mucosal and submucosal tissue. Our aim was to assess the technical feasibility, safety, and efficacy of PED using the EndoRotor® device.

Study Design: This was an Institutional Review Board–approved, multicenter, retrospective review. Patients underwent PED with the EndoRotor® device from August 2018 to September 2019 at 4 high-volume U.S. centers. Patient demographics, indication for PED, and procedural and histopathologic data were recorded.

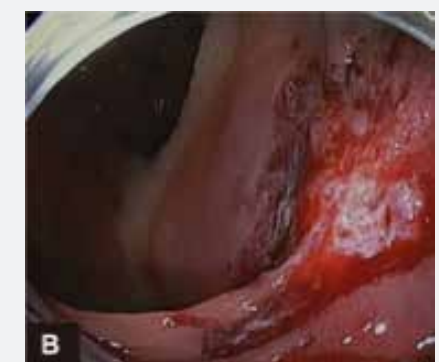Key Findings: Thirty-four patients underwent PED (41 lesions). The most common indications for PED were colon polyps (18, 52.9%) and Barrett’s esophagus (8, 23.5%). Most lesions (35, 85.4%) were resected previously for the same indication using standard techniques. Technical success was achieved in 97.6% of lesions (n = 40). Clinical success was achieved in most patients who underwent a follow-up examination (19, 79.2%). Intraprocedural bleeding (in 10 patients) was managed endoscopically; no EndoRotor®-related perforations occurred. Three postprocedural adverse events occurred: self-limited chest pain in 1 patient and delayed bleeding in 2.

Conclusion: The EndoRotor® is a novel, effective, and safe PED device for endoscopic resection of flat and polypoid lesions in the colon and foregut. It may have a promising role in the endoscopic management of naïve and scarred mucosal lesions based on this initial experience. Further prospective studies are needed to clarify its role in endoluminal resection.

A-Before



B-After



Intended Use: Scarred Lesions/Residual Tissue

The EndoRotor EPR™ Catheter is intended for use in endoscopic procedures by a trained gastroenterologist to resect and remove tissue, not intended for biopsy, of the gastrointestinal (GI) system including post-endoscopic mucosal resection (EMR) tissue persistence with a scarred base and residual tissue from the peripheral margins following EMR.

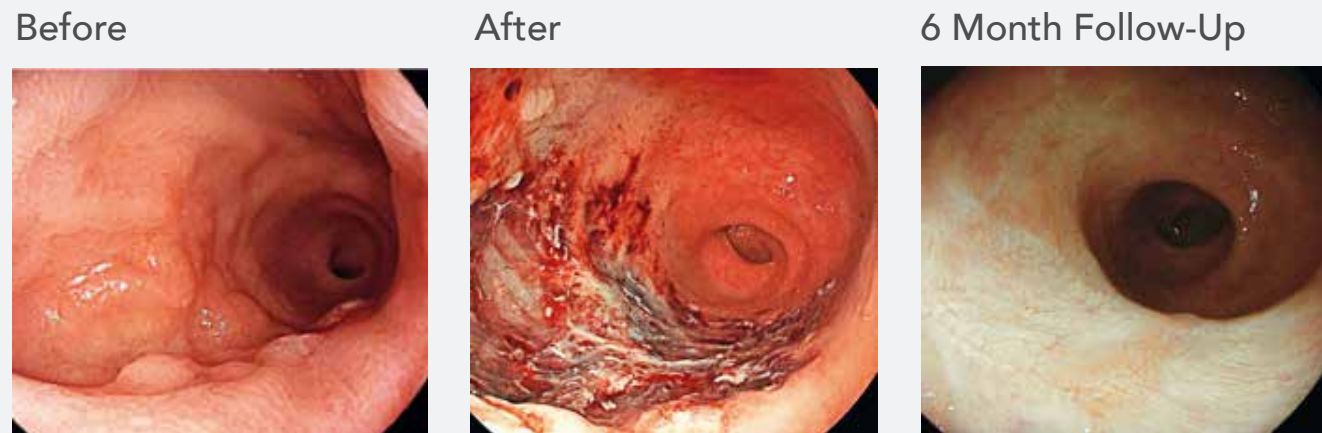Cutting-edge effective endoscopic technique to remove scarred polyps.²

Pellegatta G., Mangiavillano B., Maselli R., Galtieri P.A., Bhandari P., Ferdinando D.A., Badalamenti M., Fugazza A., Anderloni A., Ferrara E.C., Carrara S., Di Leo M., Repici A.,
Published in Endoscopy 2020

Background: Scarred polyps, especially those larger than 20mm, are challenging to resect using conventional endoscopic mucosal and submucosal resection techniques. The EndoRotor® (Interscope®, Inc.) is a novel automated mechanical endoscopic resection system designed for use in the gastrointestinal tract for tissue dissection and resection. Its use has been demonstrated to be a safe and effective technique in the management of scarred polyps. We describe a case of an 80-year-old woman with a large recurrent polyp in the rectum. Three previous attempts at eradication had been made using endoscopic mucosal resection (EMR) plus argon plasma coagulation (APC).

Treatment: Surveillance colonoscopy performed 1 year after the last EMR plus APC showed, 3cm above the anal verge, a scarred granular laterally spreading tumor (LST-G) with a diameter of 40mm, hemi circumferential and with an adenomatous pit pattern (Kudo III) on evaluation with digital chromoendoscopy (BLI/LCI). Because of the scar tissue, which represented 60% of the lesion and made mucosal or submucosal resection impossible, we decided to treat the patient with the EndoRotor® technique. After circumferential marking with APC and submucosal injection, the EndoRotor® catheter was inserted into the instrument channel and the solid black line at the tip of the catheter was positioned directly above the lesion. Using the EndoRotor®, complete resection was achieved without bleeding or other intraoperative or postoperative adverse events. PuraStat, a self-assembling peptide used for hemostasis, was applied prophylactically over the resection base at the end of procedure. The patient was discharged the same day. The resected tissue fragments were collected, and histological assessment identified a tubulovillous adenoma with low-grade dysplasia.

Follow-Up: The subsequent 6-month endoscopic follow-up did not show any recurrence or stricture. This case demonstrates the use of a novel nonthermal device, EndoRotor®, as a safe and effective technique in challenging management of scarred polyps.



Endoscopic management of pancreatic necrosis using the EndoRotor®.³

Stadler A., Knabe M., May A., Published in Z Gastroenterol 2019

Objective: Benign colorectal neoplasia are commonly resected using snare resection or endoscopic submucosal dissection (ESD). These methods are safe, but just the piecemeal resection in flat adenomas greater than 20mm harbor a relevant risk of recurrence. Interventional endoscopic therapy of recurrent lesions can be challenging, even in expert hands due to a high risk of complications. While smaller, scarred recurrent adenomas less than 20mm are suitable for endoscopic full-thickness resection, hitherto larger ones have had to be removed with more laborious, time-consuming and costly endoscopic methods, or had to undergo surgery.

Study Design: The EndoRotor® is a novel non-diathermic resection system for benign neoplasia in the gastrointestinal tract. The tissue is aspirated into an opening at the tip of a flexible resection catheter, dissected by means of a rotating blade on the inside of the catheter and finally transported into a tissue trap.

Key Findings: We present the case of a 79-year-old female patient with a large recurrent adenoma of a lateral-spreading tumor granular type in the rectum. Whereas a part of the adenoma could be resected with ESD, the scarred parts were not amenable to traditional endoscopic methods. By using EndoRotor®, the scarred adenoma could be resected completely and without any complication.

Conclusion: Scarred adenomas pose a challenge for interventional endoscopy. In this case study, EndoRotor® proved to be a safe and viable method and a new resection option for complicated scarred rectal adenomas.

Safety and efficacy of a novel powered endoscopic debridement tissue resection device for management of difficult colon and foregut lesions: first multicenter U.S. experience.⁴

Ayub K., Diehl D., Infantolino A., Enslin S., Bittner K., Tariq R., Ashan N., Aslam R., Kaul V., Published in *American Journal of Gastroenterology* 2019

Objective: Benign colorectal neoplasia are commonly resected using snare resection or endoscopic submucosal dissection (ESD). These methods are safe, but just the piecemeal resection in flat adenomas greater than 20mm harbor a relevant risk of recurrence. Interventional endoscopic therapy of recurrent lesions can be challenging, even in expert hands due to a high risk of complications. While smaller, scarred recurrent adenomas less than 20mm are suitable for endoscopic full-thickness resection, hitherto larger ones have had to be removed with more laborious, time-consuming and costly endoscopic methods, or had to undergo surgery.

Study Design: The EndoRotor® is a novel non-diathermic resection system for benign neoplasia in the gastrointestinal tract. The tissue is aspirated into an opening at the tip of a flexible resection catheter, dissected by means of a rotating blade on the inside of the catheter and finally transported into a tissue trap.

Key Findings: We present the case of a 79-year-old female patient with a large recurrent adenoma of a lateral-spreading tumor granular type in the rectum. Whereas a part of the adenoma could be resected with ESD, the scarred parts were not amenable to traditional endoscopic methods. By using EndoRotor®, the scarred adenoma could be resected completely and without any complication.

Conclusion: Scarred adenomas pose a challenge for interventional endoscopy. In this case study, EndoRotor® proved to be a safe and viable method and a new resection option for complicated scarred rectal adenomas.

A novel non-thermal resection tool in endoscopic management of scarred polyps⁵

Kandiah K, Subramaniam S, Chedgy F, Thayalasekaran S, Venetz D, Aepli P, Bhandari P., Published in *Endoscopy Int. Open*, 2019

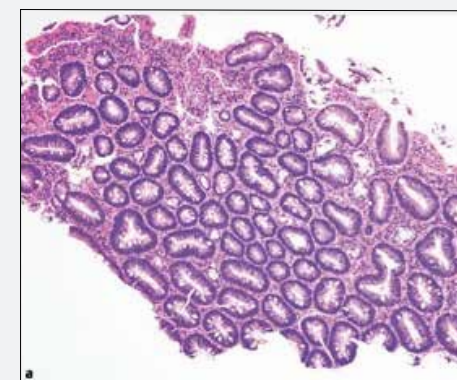
Objective: Scarred polyps are challenging to resect using conventional endoscopic mucosal resection (EMR) techniques. The aim of this pilot study was to assess the feasibility of the EndoRotor® device in resecting scarred polyps arising from previous endoscopic resection attempts.

Study Design: This was a prospective pilot study of patients with scarred colonic polyps treated using EndoRotor carried out in two centers.

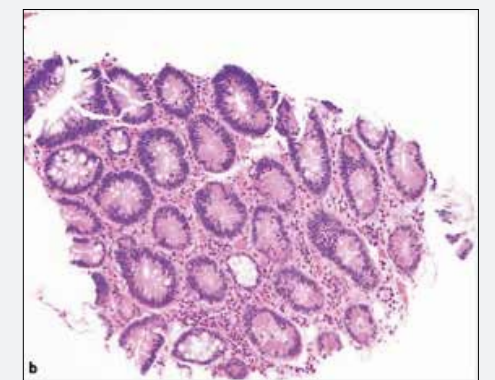
Key Findings: A total of 19 patients were included in this study. The overall cure rate using EndoRotor® was 84%; 10 patients (52.6%) achieved cure after one attempt and six patients (31.5%) achieved cure after two attempts. A total of three patients who had polyp recurrence after the first EndoRotor® resection were referred for either endoscopic submucosal dissection (2 patients) or surgery (1 patient) due to difficult access. There were no perforations, delayed bleeding, post-polypectomy syndrome or complications requiring surgery.

Conclusion: In this pilot study, the novel non-thermal device (EndoRotor®) has been demonstrated to be a safe and effective technique in challenging management of scarred polyps. Further randomized controlled trials comparing this technique with APC, hot avulsion, ESD and endoscopic full-thickness resection are required to ascertain the utility of EndoRotor® in the hands of non-expert endoscopists.

Standard Biopsy Forcep Specimen



EndoRotor® Specimen



Sigmoid colon polyp EMR with novel endoscopic morcellator⁶

Surkunalingam N, Das A, Khosravi F, Sachdev M., Published in VideoGIE 2018

Microscopic residual lesion after apparent complete EMR of large lesions: evidence for mechanism of recurrence⁷

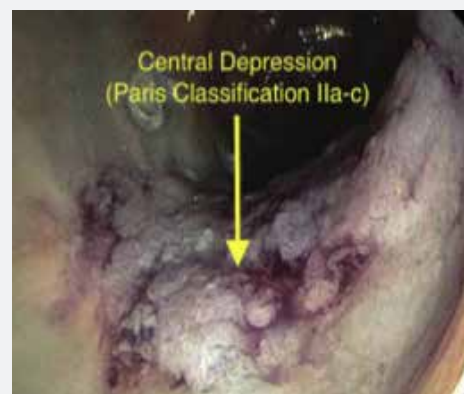Emmanuel A., Gulati S, Ortenzi M., Burt M., Hayee B., Haji M., Published in GUT 2018

Background: A 65-year-old woman underwent screening colonoscopy and was found to have a 60-mm polyp that was removed in piecemeal fashion by another gastroenterologist. The initial pathologic examination noted tubular adenoma with high-grade dysplasia. Repeated surveillance colonoscopy 3 months later noted a 20-mm area of residual focus that was draping over a fold. Examination of repeated biopsy specimens taken at that time noted tubular adenoma without high-grade dysplasia or malignancy. Owing to risk factors, such as prior high-grade dysplasia and the location and characteristics of the polyp, the patient was referred to a colorectal surgeon for evaluation. After discussion with the surgical team, the patient opted to defer surgical intervention and pursue endoscopic treatment.

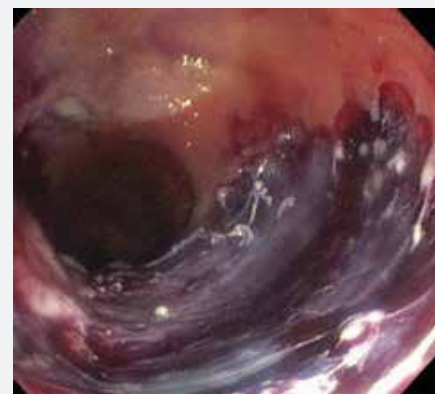Treatment: The patient was sent to our center for further treatment. An initial attempt at endoscopic submucosal dissection (ESD) was made; however, owing to suboptimal lift, the decision was made to transition to EMR. The lesion was a Paris classification IIa+c lesion. Because it was not possible to obtain adequate tissue apposition and achieve resection with the snare despite multiple techniques, the decision was made to transition to a salvage EMR technique with use of a novel endoscopic morcellator. Using the morcellator device, we were able to obtain complete resection down to the submucosal layer without penetration into the muscularis propria. The patient tolerated the procedure well without any immediate adverse events.

Follow-Up: The patient was seen at a follow-up visit for repeated surveillance colonoscopy in 4 months. No visible residual focus was noted. Examination of biopsy specimens from the site of the previous resection noted no further adenomatous tissue. Our prolonged time of 20 minutes for the initial resection may be secondary to our limited experience with the novel endoscopic device. We hope that resection times will decrease with increased use of, and comfort with, this device. Another drawback was the inability to obtain an en-bloc specimen.

Before



After



Objective: Endoscopic mucosal resection (EMR) of large colorectal superficial neoplastic lesions (CSNL) is associated with significant recurrence and the risk of recurrence is significantly higher with piecemeal EMR (pEMR). The mechanism for recurrence has not been proven but has been postulated to occur as a result of microscopic areas of residual adenoma left between areas of sequential snare capture during pEMR. We aimed to determine the incidence of residual microadenoma in apparently normal mucosa left at the margin of the defect following EMR.

Study Design: Following EMR/pEMR of 31 large CSNL, the base and margin of the resulting defect were examined with magnification chromoendoscopy and NBI/BLI to ensure complete resection. The apparently normal mucosa at the defect margin was then resected using the EndoRotor® device, removing and sampling the full extent of the defect margin. Areas of submucosal fibrosis or diathermy artefact at the base were also sampled if present. Data on the lesion characteristics, resection technique, number of pieces for pEMR, histopathology findings of the lesion and the mucosa at the margin were collected.

Key Findings: Mean lesion size was 46.7 mm (range 32 mm-130 mm). Mucosa at the defect margin was sampled in all cases and 100% of the margin was achieved in 28 (90%). Final histopathology of resected lesions was adenoma in 27 (87%), serrated adenoma in 2 (6%) and adenocarcinoma in 2. Microscopic residual lesion was detected in the margin of apparently normal mucosa in 4 cases (13%). In 3 cases this was adenoma with low grade dysplasia and in one case a serrated lesion with no dysplasia was found in at the margin of a resected tubular adenoma. Microscopic residual lesion was detected in the base in 4 cases: 1 was microadenoma, 2 were serrated lesions without dysplasia in the base of resected adenomas and 1 was residual adenocarcinoma. There was no association with pEMR in >3 pieces and residual microscopic lesion or pEMR ≤3 pieces (OR 0.89, 95% CI 0.16-4.8, p=0.89). There were no complications.

Conclusion: To our knowledge, this is the first series examining the findings after continuous sampling of the full circumferential margin of apparently normal mucosa left at the defect after EMR of large CSNL. Despite examination with magnification suggesting complete resection, microscopic residual lesion at the margin was present in 13%. This study provides evidence that microscopic residual lesion left after EMR underlies the pathophysiology of recurrence and lends support for techniques that continuously resect or ablate the circumferential margin of the defect to reduce recurrence.

The EndoRotor® – a novel endoscopic device for mucosal resection: a case report.⁸

Tillinger et al. Published in J Gastroenterol Hepatol Erkrank, 2017

Background: Endoscopic removal of colonic polyps is associated with reduced mortality from colorectal cancer. Large non-pedunculated polyps are safely removed with snares by means of endoscopic mucosal resection (EMR). However, reoccurrence of polyps after EMR may occur in up to 20% of patients and further removal may be hampered due to the formation of scar tissue. Furthermore, the histologic examination may be difficult due to thermic alteration of the tissue samples by electrocautery.

Here we present a novel device for EMR. The EndoRotor® is a non-thermal, automated mechanical endoscopic resection system, designed to remove benign mucosal neoplastic tissue throughout the gastrointestinal tract. It uses suction pressure to pull mucosa into a catheter, cut it by a blade rotating inside that catheter while automatically transporting the samples into a collection trap for histologic evaluation. The mucosal layer is selectively sucked into the catheter due to the different viscoelastic properties of the mucosal and the muscularis layer.

Case Report: We present the case of a 90-year-old male patient with a rectal adenoma, which was not amenable to a snare removal due to the formation of extensive scar tissue after repeated previous attempts of EMR. A surgical resection was not considered as an alternative due to serious comorbidities. The lesion extended in a length of 3 cm over the whole circumference. The proximal part was located on a scarred stenosis, yet passable with the endoscope. By using the EndoRotor® the whole lesion could be removed in two sessions. Minor bleeding was controlled by means of adrenalin-injection and coagulation with argonplasma. No further complications occurred.

Discussion: The EndoRotor® is a novel device for EMR. In the present case the EndoRotor® proved to be effective and safe, in particular for scarred polyps non amenable to snare resection the device may be a valuable tool. Further studies addressing efficacy and safety will determine its role in interventional endoscopy.

The EndoRotor®: endoscopic mucosal resection system for non-thermal and rapid removal of esophageal, gastric, and colonic lesions: initial experience in live animals⁹

Hollerbach et al. Published in Endoscopy Int. Open, 2016

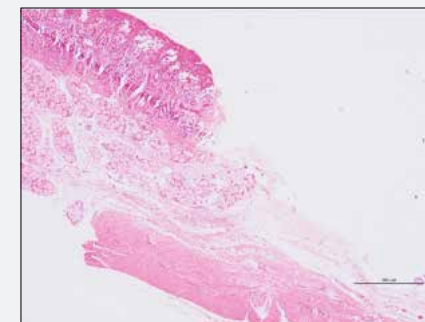
Background: The EndoRotor® is a novel, non-thermal, automated mechanical endoscopic resection system designed to remove benign mucosal neoplastic tissue throughout the gastrointestinal tract. It uses suction pressure to pull in mucosa and rapidly and precisely cut it while automatically transporting the samples to a collection trap for later histologic evaluation.

Study Design: To study the technical properties and therapeutic potential of this new tool, we performed multiple upper and lower gastrointestinal endoscopic mucosal resections in three healthy live pigs. Animals were anesthetized and kept artificially ventilated while two physicians performed multiple qualitative mucosal resections on various sites of the pigs' esophagus, stomach, duodenum, and colon.

Key Findings: Rapid resection of flat and slightly elevated mucosa up to several centimeters in size/diameter was performed. No major bleeding occurred during and after resections. When used properly, no gastrointestinal wall perforations occurred during superficial resections. Perforations in the colon were only observed when the device was deliberately pushed against deeper sub-mucosal layers or when exceptional force was applied to penetrate the gastrointestinal wall. Histologic specimens showed complete mucosal removal at resection sites. The flexible catheter could be moved and directed towards most of the areas of interest in the gastrointestinal tract.

Conclusion: The EndoRotor® rapidly and easily resects flat and slightly elevated gastrointestinal mucosa with a short learning curve. Future studies in humans should be performed to prove its ability for large-area mucosal resections in benign conditions such as laterally spreading adenomas in the colon, or Barrett's mucosa in the distal esophagus.

Intact muscularis and serosa post resection



EndoRotor EPR Catheter™



Incidence of microscopic residual adenoma after complete wide-field endoscopic resection of large colorectal lesions: evidence for a mechanism of recurrence¹⁰

Emmanuel A., Gulati S., Ortenzi M., Burt M., Hayee B., Haji A., Published in GIE 2021

Objective: EMR of large (2 cm or greater) nonpedunculated colorectal polyps (LNPCPs) is associated with high rates of recurrent/residual adenoma, possibly because of microadenoma left at the margin of resection. Data supporting this mechanism are needed. We aimed to determine the incidence of residual microadenoma at the defect margin and defect base after EMR.

Study Design: We performed a retrospective observational study of patients undergoing EMR of large LNCPs with the lateral defect margin further resected using the EndoRotor device (Interscope Medical, Inc, Worcester, Mass, USA) after confirming no visible residual adenomatous tissue. Aspects of the defect base were also resected in selected patients. Patients underwent surveillance at 3 to 6 months.

Key Findings: Resection of the normal defect margin was performed in 41 patients and of aspects of the base in 21 patients. Mean lesion size was 43.0 mm (range, 20-130). Microscopic residual lesion was detected in the margin of apparently normal mucosa in 8 cases (19%). In 7 cases this was an adenoma, and in 1 case a serrated lesion was found at the margin of a resected tubular adenoma. Microscopic residual lesion was detected at the base in 5 of 21 cases. Residual/recurrent adenoma was detected in 2 patients. Neither had residual microadenoma at the lateral margin or base detected after the primary resection.

Conclusion: Microscopic residual adenoma after wide-field EMR was detected in 19% of cases at the apparently normal defect margin and at the resection base in 5 of 21 cases. This study confirms the presence of residual microadenoma after resection of LNCPs, providing evidence for the mechanism of recurrence.

¹Kaul, Vivek, et al. Safety and efficacy of a novel powered endoscopic debridement tissue resection device for management of difficult colon and foregut lesions: first multicenter U.S. experience. *Gastrointestinal Endoscopy*, 2020, doi:10.1016/j.gie.2020.06.068.

²Pellegatta G, Mangiavillano B, Maselli R, Galtieri PA, Bhandari P, Ferdinando DA, Badalamenti M, Fugazza A, Anderloni A, Ferrara EC, Carrara S, Di Leo M, Repici A. Cutting-edge effective endoscopic technique to remove scarred polyps. *Endoscopy*. 2020;10(S1):S328. doi: 10.1055/s-0040-1705060

³Stadler A, Knabe M, May A. Endoskopische Abtragung eines vernarbten Adenoms im Rektum mittels EndoRotor® [Endoscopic resection of a scarred rectal adenoma using EndoRotor®]. *Z Gastroenterol*. 2019; Oct;57(10):1226-1229. doi: 10.1055/a-0991-0839. German, with English abstract.

⁴Ayub K, Diehl D, Infantolino A, Enslin S, Bittner K, Tariq R, Ashan N, Aslam R, Kaul V. Safety and efficacy of the novel EndoRotor® mucosal resection system: first multicenter USA experience. *Am J Gastroenterol*. 2019;Oct;114:S502-S503. doi: 10.14309/01.ajg.0000593000.03914.0d.

⁵Kandiah K, Subramaniam S, Chedgy F, Thayalasekaran S, Venetz D, Aepli P, Bhandari P. A novel non-thermal resection tool in endoscopic management of scarred polyps. *Endosc Int Open*. 2019;Aug;7(8):E974-E978. doi: 10.1055/a-0838-5424.

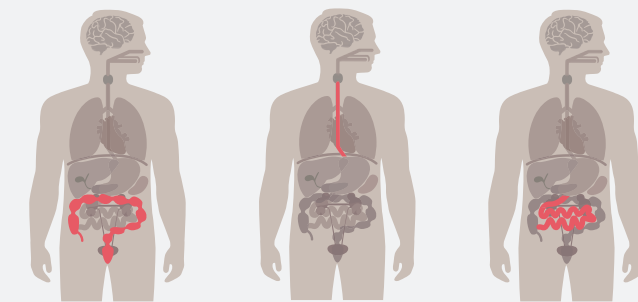
⁶Surkuningam N, Das A, Khosravi F, Sachdev M. Sigmoid colon polyp EMR with novel endoscopic morcellator. *VideoGIE*. 2018; Jun;3(6)191-192. doi: 10.1016/j.vgie.2018.04.006.

⁷Emmanuel A, Gulati S, Ortenzi M, Burt M, Hayee B, Haji M. Microscopic residual lesion after apparent complete EMR of large lesions: evidence for mechanism of recurrence. *Gut*. 2018; Jun;67:A10. doi: 10.1136/gutjnl-2018-BSGAbstracts.18.

⁸Tillinger W, Reckendorfer H. Der Endorotor® – Ein neues endoskopisches Resektionssystem: Fallbericht [The EndoRotor® – a novel endoscopic device for mucosal resection: a case report]. *J Gastroenterol Hepatol Erkrank*. 2017;15(1)10-13. <https://www.kup.at/kup/pdf/13815.pdf>. German, with English abstract.

⁹Hollerbach S, Wellmann A, Meier P, Ryan J, Franco R, Koehler P. The EndoRotor®: endoscopic mucosal resection system for non-thermal and rapid removal of esophageal, gastric, and colonic lesions: initial experience in live animals. *Endosc Int Open*. 2016;4(4):E475-E479. doi: 10.1055/s-0042-105207.

¹⁰Emmanuel, A., Williams, S., Gulati, S., Ortenzi, M., Gunasingam, N., Burt, M., ... Haji, A. (2021). Incidence of microscopic residual adenoma after complete wide-field endoscopic resection of large colorectal lesions: evidence for a mechanism of recurrence. *Gastrointestinal Endoscopy*. <https://doi.org/10.1016/j.gie.2021.02.010>



For more information visit www.interscopemed.com
or contact Customer Service:

USA

Tel: 800-461-4289 (toll-free in U.S.)
Email: info@interscopemed.com



Interscope, Inc.
200 Commerce Drive
Northbridge, MA 01534
USA
TEL: +1-800-461-4289
0031 (0) 73-3032541
www.interscopemed.com



EMERGO EUROPE
Prinsessegracht 20
2514 AP The Hague
The Netherlands
EMERGObyUL.com

