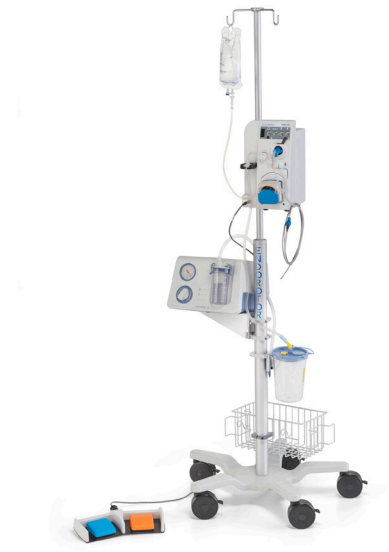

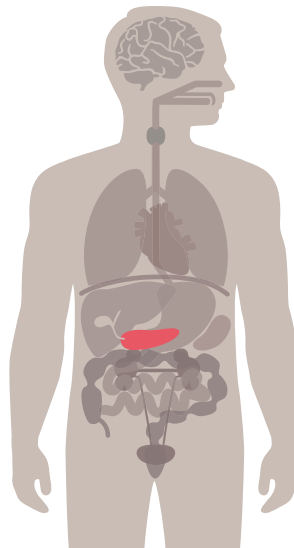
Necrosectomy

- Abstract Summaries
- Posters
- Case Reports



EndoRotor®

EndoRotor® PED™



Intended Use: WON/WOPN

The EndoRotor® PED™ Catheter is intended for resection and removal of necrotic tissue in symptomatic WOPN/WON after patients have undergone endoscopic ultrasound (EUS) guided drainage.

Warning: The EndoRotor® device should not be used in patients with known or suspected pancreatic cancer as per the assessment of the treating physician. Refer to “Instructions for Use” for additional information.

²Prospective Trial Evaluating The Safety And Effectiveness Of The Interscope Endorotor® Resection System For Direct Endoscopic Necrosectomy Of Walled-Off Pancreatic Necrosis (Endorotor Den Trial).

Stassen et al. Published in GIE 2020

Objective: Debridement of infected walled-off pancreatic necrosis (WOPN) is indicated to treat ongoing infection and sepsis-related multi-organ failure. The lack of dedicated and effective accessories results in the need for time-consuming repetitive procedures. In the published literature a mean of 4 endoscopic procedures is typically needed to clear the necrotic cavity using conventional accessories. The aim of this study was to evaluate the use of a new 3.1 mm flexible microdebrider catheter (the EndoRotor® powered endoscopic debridement system) to remove solid debris under direct endoscopic visualization.

Study Design: 10 international sites enrolled patients requiring direct endoscopic necrosectomy (DEN) in a prospective study. Cases with WOPN size of ≥ 6 mm and ≤ 22 mm, with $>30\%$ solid component based on computed tomography (CT), were included. Outcomes such as successful clearance of necrosis ($\geq 70\%$ removal of necrotic debris at 21 days, procedural time, number of procedures until resolution, adverse events, length of hospital stay and quality of life were included in analyses.

Key Findings: Between November 2018 and August 2019, 30 patients (mean age 55 years, 60% male) underwent necrosectomy using the EndoRotor® resection system. 15/30 (50%) achieved complete debridement in one session, and 21/30 (73%) achieved complete debridement after 2 sessions. No EndoRotor®-associated adverse events were reported. One patient died during the follow up period due to shock and multi-organ failure, unrelated to the treatment with the EndoRotor®. Mean time between LAMS or SEMS placement and debridement was 14 days. A median of 2.1 interventions (range 1-7) was required. Mean EndoRotor® procedure time was 71 minutes (SD 37 minutes). Mean overall endoscopic procedure time was 117 (SD 50 minutes). Baseline necrotic debris was 69% (SD 20%) and the mean reduction of solid necrosis of 68% (SD 29%), 54% (SD 34%), 58% (SD 36%) and 34% (SD 29%) was achieved after the first, second, third and fourth procedure, respectively. At the 21-day follow-up, the mean reduction in necrosis volume from baseline was 90% (SD 19%). Average duration from the start of necrosectomy until discharge was 16 days (SD 27 days).

Conclusion: Direct endoscopic necrosectomy using the EndoRotor® resection system is a safe and effective treatment for patients with WOPN. Necrosectomy using the EndoRotor® resection is associated with a lower number of endoscopies and shorter procedural time when compared to published literature.

³Experience with EndoRotor®-XT for endoscopic necrosectomy in patients with acute necrotic pancreatitis at a tertiary care center.

Ahmed et al. Published in GIE 2020

Objective: Acute necrotic pancreatitis is a devastating disease with mortality rates ranging from 26–86%. The recent development of a lumen apposing metal stent (LAMS) has improved endoscopic therapies. The main limitation is the lack of dedicated endoscopic tools to clear the necrotic tissue. The EndoRotor® XT is a novel mechanical endoscopic resection system designed for this purpose. So far only 2 cases of pancreatic necrosis treated by EndoRotor® have been described in the literature. We share our experience with the use of EndoRotor® in 4 patients.

Study Design: A retrospective chart review of all cases of pancreatic necrosis in which EndoRotor® mechanical debridement was employed. All patients underwent cystgastrostomy with the placement of a 15x10mm LAMS at a prior endoscopy and presented for follow up necrosectomy. A double-channel therapeutic endoscope was used for EndoRotor® debridement. All patients had greater than 30% cyst wall involvement of necrosis.

Key Findings: Four patients, all males with an average age of 49 had a mean maximal axial cyst diameter of 151 mm and underwent an average of 1.25 (1 patient had 2 sessions) EndoRotor® mechanical debridement necrosectomies. Complete cyst resolution was observed in 75% of patients (one is currently still being treated) with the mean time to cyst resolution being 84 days. The mean length of hospital stay and time to discharge after EndoRotor® treatment was 33 and 19 days, respectively. There were no patient complications and only one technical complication of the EndoRotor® getting caught on the LAMS. This was remedied by the removal of the stent and the EndoRotor® without any further sequelae.

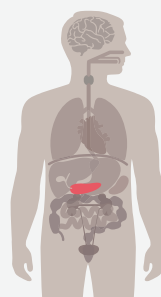
Conclusion: Evolving technologies for endoscopic debridement present opportunities to improve patient outcomes in pancreatic necrosis. Our initial experience with the EndoRotor® demonstrates promising results. None of our patients to date required additional surgical or interventional radiology procedures. One patient was managed as an outpatient, and 2 others were able to achieve early discharge. One technical complication was observed but the procedure was well tolerated by all patients. Further studies comparing the additive benefit of the EndoRotor® are needed.

⁴Endoscopic management of pancreatic necrosis using the EndoRotor®.

Mangas-Sanjuan et al. Published in Endoscopy 2020



A 62 years-old-man with severe acute necrotizing pancreatitis had previously undergone unsuccessful conventional endoscopic management of pancreatic necrosis. Thereafter, we decided to use the EndoRotor® system. It consists of a disposable catheter with a rotating blade at its distal end, which is connected to a suction and continuous irrigation pump. It is controlled by two pedals: one activates the rotation of the blade the other activates the aspiration. The removal of necrotic tissue is only performed when the aspiration is activated, which guarantees the safety and prevents complications. Three procedures using the EndoRotor® were successfully carried out without adverse events despite the presence of the SMA inside the collection.



⁵Endoscopic microdebrider-assisted necrosectomy for walled-off pancreatic necrosis

Schlag et al. Published in Endoscopy 2020

Objective: Debridement of infected walled-off pancreatic necrosis (WOPN) is indicated to treat ongoing infection and sepsis-related multi-organ failure. The lack of dedicated and effective accessories results in the need for time-consuming repetitive procedures. The aim of this prospective international multicenter study is to evaluate the use of a new 3.1 mm flexible microdebrider catheter (EndoRotor®) to remove solid debris under direct endoscopic visualization in patients with WOPNs.

Study Design: All patients underwent prior CT scan which had to show WOPN of ≥ 6 cm and ≤ 22 cm in size with $\geq 30\%$ solid component. Endoscopic drainage (by either LAMS, SEMS or DPS) was carried out at least three days before endoscopic microdebrider-assisted necrosectomy was performed through the gastrotoma under direct visualization. Adverse events (AE), procedure times, number of procedures until resolution, percentage decrease of solid necrosis per session, decrease of WOPN size on follow-up CT scans (21 days after final session) and time to discharge were documented.

Key Findings: Here we present interim data of the first 12 patients who underwent microdebrider-assisted necrosectomy within the study. No microdebrider-associated adverse events, including bleeding were reported. A mean of 1.8 interventions (range 1-4) were required with an average microdebrider procedure time of 77 minutes and a total procedure time of 180 minutes. There was a mean 63.0% reduction of solid necrosis after the first session. The mean decrease of cavity size was 86.8% comparing pre- and post-procedural CT scans. Time from microdebrider-assisted necrosectomy to discharge averaged 6 days (range 0-12 days).

Conclusion: Microdebrider-assisted necrosectomy for WOPN is a feasible and safe procedure that can provide very effective endoscopic clearance of solid debris without device-associated adverse events.

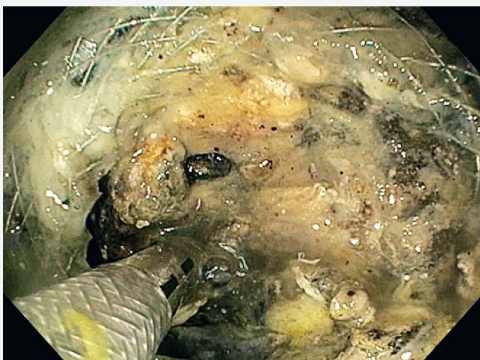
Endoscopic microdebrider-assisted necrosectomy for walled-off pancreatic necrosis.

Rizzatti et al. Published in *Endoscopy 2020 International Open 2020*

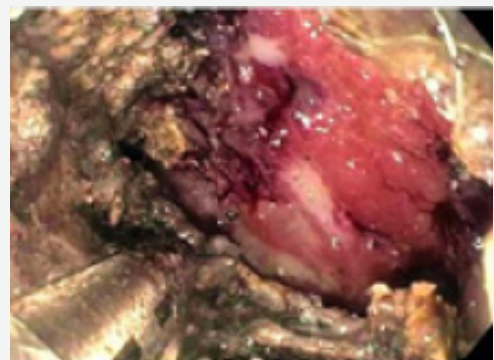
A 67-year-old man with a 15-cm pancreatic necrotic collection was transferred to our unit after 2 months' hospitalization for necrotizing pancreatitis. His condition was poor, with decreased mental status, high fever, neutrophilic leukocytosis (white blood cells $27.6 \times 10^9/L$, neutrophils 93.1%), and signs of sepsis (C-reactive protein 150.5 mg/L, procalcitonin 9.83 ng/mL).

Emergency endosonography-guided drainage using a 15×10 mm Axios stent (Boston Scientific, Marlborough, Massachusetts, USA) mounted onto a cautery device was successfully performed. During the procedure a major vessel was observed inside the collection. He was sent for embolization but angio-computed tomography revealed the vessel to be the superior mesenteric artery (SMA) and embolization prior to direct endoscopic necrosectomy (DEN) was aborted. A decision to pursue DEN was made and the EndoRotor® system (Interscope, Inc., Whitinsville, Massachusetts, USA) which allows constant endoscopic visualization during necrosectomy was utilized. The procedure was performed using a dedicated EndoRotor® XT catheter, high rotating speed (1700 rpm), and progressive increase of suction up to 60 L/min, with careful visualization of the site at which the catheter was active.

Necrotic collection



Superior mesenteric artery



⁷Preliminary report on the safety and utility of a novel automated mechanical endoscopic tissue resection tool for endoscopic necrosectomy: a case series.

Bruno et al. Published in Endoscopy International Open 2020

Objective: Endoscopic drainage of walled-off necrosis and subsequent endoscopic necrosectomy has been shown to be an effective step-up management strategy in patients with acute necrotizing pancreatitis. One of the limitations of this endoscopic approach however, is the lack of dedicated and effective instruments to remove necrotic tissue. We aimed to evaluate the technical feasibility, safety, and clinical outcome of the EndoRotor®, a novel automated mechanical endoscopic tissue resection tool, in patients with necrotizing pancreatitis.

Study Design: Patients with infected necrotizing pancreatitis in need of endoscopic necrosectomy after initial cystogastrosocopy, were treated using the EndoRotor®. Procedures were performed under conscious or propofol sedation by six experienced endoscopists. Technical feasibility, safety, and clinical outcomes were evaluated and scored. Operator experience was assessed by a short questionnaire.

Key Findings: Twelve patients with a median age of 60.6 years, underwent a total of 27 procedures for removal of infected pancreatic necrosis using the EndoRotor®. Of these, nine patients were treated de novo. Three patients had already undergone unsuccessful endoscopic necrosectomy procedures using conventional tools. The mean size of the walled-off cavities was 117.5 ± 51.9 mm. An average of two procedures (range 1 – 7) per patient was required to achieve complete removal of necrotic tissue with the EndoRotor. No procedure-related adverse events occurred. Endoscopists deemed the device to be easy to use and effective for safe and controlled removal of the necrosis.

Conclusion: Initial experience with the EndoRotor® suggests that this device can safely, rapidly, and effectively remove necrotic tissue in patients with (infected) walled-off pancreatic necrosis.

⁸Novel endoscopic morcellator to facilitate direct necrosectomy of solid walled-off necrosis.

Thompson et al. Published in Endoscopy International Open 2020

Pancreatic walled-off necrosis (WON) is a feared late complication of acute necrotizing pancreatitis. Pancreatic WON is a well-demarcated, organized collection of necrotic tissue that can occur after severe pancreatitis. Surgical interventions for the treatment of WON have been associated with high morbidity and mortality rates. Endoscopic management including direct endoscopic necrosectomy has emerged as the treatment of choice for WON, with low complication rates, low costs, reduced time of hospitalization, and high rates of WON resolution.

Direct endoscopic necrosectomy allows debridement of necrotic tissue through the gastric or duodenal wall. This technique has demonstrated higher WON resolution rates when compared to endoscopic drainage alone, particularly in cases of WON with semi-solid necrotic material. However, direct endoscopic necrosectomy may be challenging in cases where the WON is predominantly solid.

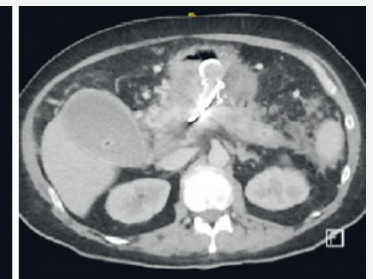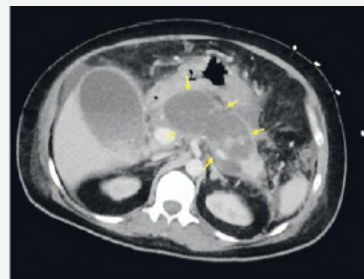
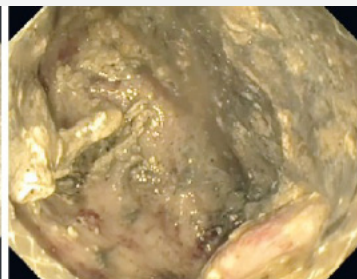
We present a case of a 70-year-old man with history of hypertension and chronic lymphocytic leukemia who presented to our hospital with severe acute necrotizing pancreatitis. After initial improvement, he developed fevers and leukocytosis on day 35 of his hospital admission. Computed tomography imaging revealed a 7×6-cm WON with a significant solid component (80%). Given these findings, he underwent endoscopic cystogastrostomy using a lumen-apposing metal stent (LAMS), followed by direct endoscopic necrosectomy with the assistance of a novel endoscopic morcellator device. This resulted in successful mechanical debridement and liquefaction of solid necrosis, which was followed by lavage with bacitracin–saline solution. After lavage, a 10-Fr double-pigtail plastic stent was placed within the LAMS into the WON. Imaging revealed complete resolution of the WON 6 weeks later, and both stents were successfully removed.

Pre

Post

Pre

Post



EndoRotor® use to manage walled-off pancreatic necrosis; first UK experience.

Geraghty et al. Published in Gut 2019

Objective: 20% of patients with acute pancreatitis develop necrosis, which has a poor prognosis and significant mortality rate. Endoscopic necrosectomy is the primary intervention in the management of walled-off pancreatic necrosis (WOPN). After insertion of a lumen-apposing self-expanding metal stent (LASEMS), necrosis is removed using tools such as snares and forceps. Multiple procedures are often required, with repeated insertion of the endoscope into the cavity causing patient discomfort. EndoRotor® is a through-the-scope catheter with a rotating blade, cutting tissue which is then drawn into the catheter via suction. We present the first UK case series of EndoRotor® use for endoscopic necrosectomy. We aimed to evaluate the feasibility, safety and efficacy of its use in clearing WOPN.

Study Design: A 54 year old female developed a 19 cm x 8 cm area of WOPN as a consequence of acute pancreatitis. A LASEMS was inserted and EndoRotor® necrosectomy was performed five days later. Most of the necrotic tissue was cleared and the procedure was well tolerated. Final clearance was completed with a further snare necrosectomy 6 days later. Imaging confirmed a significant reduction in the cavity size (8cm x 2cm) and the patient was discharged. A 56 year old female was admitted with acute pancreatitis and discharged home after 12 days. She was later admitted for elective cholecystectomy but became unwell. A CT found a 28cm x 9cm area of WOPN. A LASEMS was inserted and a necrosectomy was performed two days later. All visible necrosis was removed using EndoRotor® four days later. Later examination showed some residual necrosis within a well healing cavity, requiring no further intervention. A 48 year old male was admitted with acute severe pancreatitis, developing multiorgan failure requiring ICU care. A CT confirmed an 18cm x 12cm pancreatic collection and a LASEMS was inserted. The patient had four necrosectomies before having an EndoRotor® necrosectomy with good result. Two further necrosectomies were required before LASEMS removal.

Key Findings: All patients underwent EndoRotor® necrosectomy without complication. To achieve complete removal of WOPN the median number of procedures (including with EndoRotor®) was three (range 2–7).

Conclusion: As EndoRotor® draws necrosis in by suction, repeated insertion of the endoscope into the cavity is not needed, allowing greater tolerability and improved clearance of necrosis. Initial experience suggests that EndoRotor® is a safe and efficient tool for clearing WOPN.

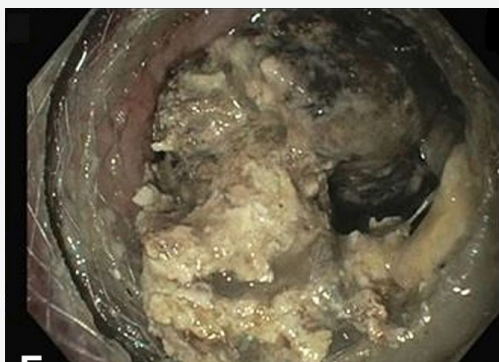¹⁰Pancreatic necrosectomy using an automated mechanical endoscopic tissue extraction device.

Sachdev et al. Published in VideoGIE 2018

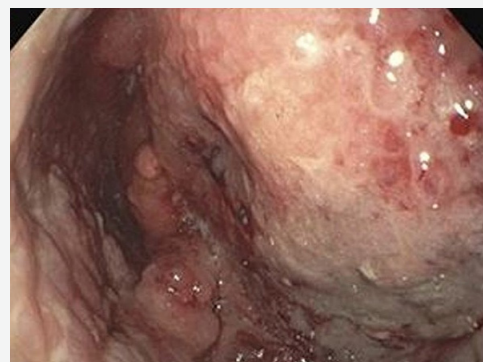Page 1 of 2

A 66-year-old man with uncontrolled diabetes mellitus and prior cholecystectomy presented to an outside hospital with symptoms of intractable abdominal pain, nausea, and vomiting. He received a diagnosis of acute pancreatitis and was treated conservatively and eventually discharged. He continued to have persistent symptoms and was admitted again. An abdominal CT scan revealed a pancreatic fluid collection (PFC) with evidence of solid debris. The patient was transferred to our facility for further evaluation and treatment. On initial evaluation, the patient was tachycardic and febrile. The results of laboratory testing were remarkable for leukocytosis and elevated lipase. The patient met the criteria for sepsis and, given the CT findings, we were concerned about an infected PFC. EUS revealed a large 70-x70-mm encapsulated fluid collection along the body of the pancreas with a moderate amount of solid debris consistent with walled-off necrosis (WON). The patient subsequently underwent EUS-guided placement of a lumen-apposing metal stent (LAMS). After placement of the LAMS, there was immediate drainage of thick purulent yellow fluid. The patient's clinical course improved, and he was discharged home. However, 8 days later he returned once again to the emergency department with a clinical picture of recurrent sepsis. A repeated CT scan of the abdomen and pelvis performed 5 days later revealed that the PFC had increased in size, and there were increasing peripancreatic inflammatory changes. Repeated upper endoscopy and EUS revealed that the initial LAMS was occluded by necrotic debris, and a large portion of the debris was removed with the use of snares and retrieval nets. A decision was made to place a secondary LAMS by use of a multiple transluminal gateway technique rather than a double-pigtail stent. Unfortunately, we did not have an appropriately sized double-pigtail stent available, and were concerned about using a longer pigtail stent because of the possibility of injuring the back wall of the cyst, based on prior experiences. Therefore, we thought that using a multiple gateway approach would potentially provide multiple drainage points. The patient underwent a total of 3 endoscopic treatments with minimal improvement.

Before



After



Given the large size of the pancreatic necroma and the recurrence of the patient's symptoms, it was thought that an alternative approach was more suitable. We discussed further options with the patient and offered him consultation with the pancreatic surgery team, repeated endoscopic necrosectomy, or consideration of a novel, off-label approach to potentially decrease the number of endoscopic procedures and multiple interventions. This particular device is designed to suction, cut, and obtain tissue samples from the edges of mucosal resection sites; however, its design can allow for controlled resection of necrotic tissue in a patient with WON. This off-label approach for repeated necrosectomy was performed (Video available online at www.VideoGIE.org). The gastric mucosa was inspected, and a large amount of necrotic debris was seen partially occluding the secondary LAMS. As the LAMS was traversed we noticed purulent fluid and a large remnant necroma. We attempted to remove it by traditional maneuvers, such as net and snare extraction; however, a significant amount of tissue remained adherent. Next, we used the automated mechanical tissue extraction device to clear the residual tissue. The 2 main elements are the console and the catheter. The catheter has a cutting blade and tubes for suction and irrigation. Before activation of the device, the angle of approach has to be adjusted to achieve the desired trajectory. This is accomplished by manipulating the rotation handle to place the cutting blade in the anticipated direction. The solid black line is located 180° from the blade, and there are hashed lines that visibly mark 90° from the cutting blade. Finally, a perpendicular solid black line indicates the center of the cutting opening. The device is used by initiating cutter rotation with depression of a foot pedal. The blades rotate clockwise and can be adjusted from 1000 to 1700 revolutions per minute. A second foot pedal initiates suction. The design of the catheter allows for the resected tissue to be aspirated immediately and collected in a trap. The procedure lasted approximately 2 hours, and complete removal of the necroma was achieved. We removed both LAMSs from the cavity, and it was left open. After the procedure, an abdominal CT scan revealed a near-complete resolution of WON as compared with prior imaging. The following day, the patient experienced significant improvement of symptoms, and he was able to tolerate food without exacerbation of nausea, vomiting, or abdominal pain. The patient's condition was deemed stable, and he was discharged home with close follow-up. Infected PFC is a significant cause of morbidity, mortality, and health-care costs. Using this novel, off-label approach with a through-the-scope automated mechanical endoscopic tissue extraction device, we were able to completely extract a large pancreatic necroma safely and effectively. An alternative to this approach includes a repeated endoscopic necrosectomy or surgical intervention. We opted to do this because we had failed to remove all of the debris using standard methods, and the patient was amenable to trying this alternative approach. This method may potentially improve patient outcomes by decreasing multiple instrumentation and exchanges, avoiding repeated procedures, and avoiding invasive surgery. However, more data and research need to be pursued to make this method competitive with current treatment strategies.

¹¹The EndoRotor, a novel tool for the endoscopic management of pancreatic necrosis.

Bruno et al. Published in Endoscopy 2018

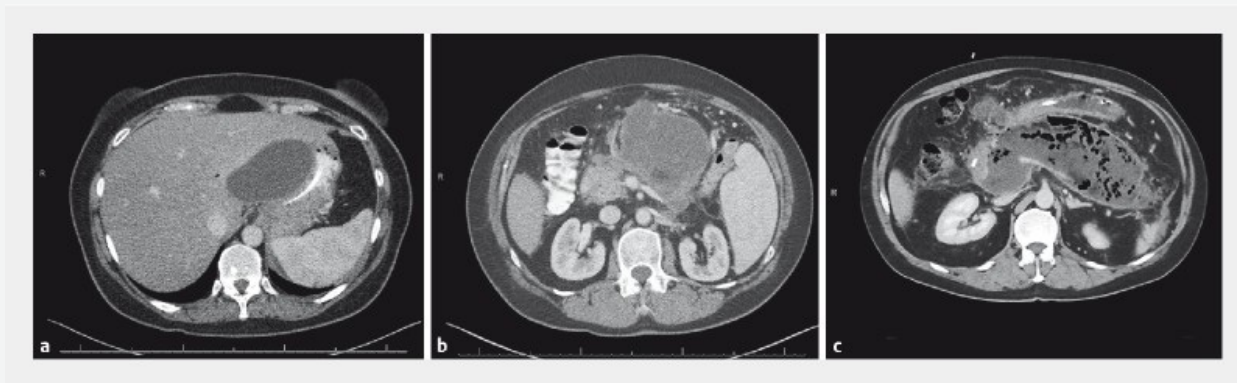Acute pancreatitis may run a severe course when pancreatic necrosis becomes infected, with mortality rates of up to 30% . Endoscopic drainage and ensuing necrosectomy have been shown to be effective in the management of pancreatic necrosis. One of the main limitations of endoscopic necrosectomy is the lack of dedicated and effective instruments to remove the necrotic tissue.

The EndoRotor® (Interscope Medical, Inc., Worcester, Massachusetts, USA) is a novel automated mechanical endoscopic resection system designed for use in the gastrointestinal tract for tissue dissection and resection with a single device; it can be used to suck, cut, and remove small pieces of tissue. The EndoRotor® catheter has a fixed outer cannula with a hollow inner cannula. A motorized, rotating cutting tool, driven by an electronically controlled console, performs tissue resection and rotates at either 1000 or 1700 revolutions per minute. The resected tissue is immediately aspirated away from the resection site, cut by the rotating inner cannula, and collected in the tissue collection trap. Both the cutting tool and the suction are controlled by the endoscopist using two separate foot pedals.

We here present the first two patients with infected walled-off pancreatic necrosis who were endoscopically treated using the EndoRotor®. Imaging of the pancreas revealed a mean necrotic collection size of 135mm in diameter. Both patients had previously been treated unsuccessfully with conventional tools in two and four procedures, respectively. Complete removal of the pancreatic necrosis was achieved with two additional procedures in each patient using the EndoRotor®. No procedure-related adverse events occurred. Both endoscopists were very satisfied about the ease of use and effective removal of necrotic tissue.

Initial experience with the EndoRotor® in two patients suggests that this device can safely, quickly, and effectively remove pancreatic necrosis.

Pre-Intervention CT Scans



¹Puli, S., Conwell, D., & Thompson, C. (2010). A Meta-analysis and Systematic Review of Endoscopic Transmural Necrosectomy (ETN) for Walled-Off Pancreatic Necrosis: 2010 Presidential Poster. *American Journal of Gastroenterology*, 105. doi:10.14309/00000434- 201010001-00142.

²Stassen, Pauline M., et al. "961 Prospective Trial Evaluating The Safety And Effectiveness Of The Interscope Endorotor® Resection System For Direct Endoscopic Necrosectomy Of Walled-Of Pancreatic Necrosis (Endorotor® Den Trial)." *Gastrointestinal Endoscopy*, vol. 91, no. 6, 2020, doi: 10.1016/j.gie.2020.03.622.

³Soota, Kaartik, et al. Experience with EndoRotor®-XT for endoscopic necrosectomy in patients with acute necrotic pancreatitis at a tertiary care center. *Gastrointestinal Endoscopy*, vol. 91, no. 6, 2020, doi:10.1016/j.gie.2020.03.1133.

⁴Mangas-Sanjuan C, Bozhychko M, Medina-Prado L, Sandra BM, Martínez B, Martínez JF Casellas JA, Aparicio JR. Endoscopic management of pancreatic necrosis using the EndoRotor®. *Endoscopy*. 2020; Apr; 52(S01):S323. doi: 10.1055/s-0040-1705043.

⁵Schlag C, Abdelhafez M, Friedrich-Rust M, Kowalski T, Lorren D, Chiang A, Schlachtermann A, Siddiqui U, Villa E, Trindade A, Benias P, Hwang JH, Hahid H, Khaleh M, Tyberg A, Koch AD, Bruno MJ. Endoscopic microdebrider-assisted necrosectomy for walled-off pancreatic necrosis. *Endoscopy*. 2020;52(S01):S29-S30. doi: 10.1055/s-0040-1704093.

⁶Rizzatti G, Rimbaş M, De Riso M, Impagnatiello M, Costamagna G, Larghi A. Endorotor®-based endoscopic necrosectomy avoiding the superior mesenteric artery. *Endoscopy*. 2020 Apr 24. doi: 10.1055/a-1151-4694.

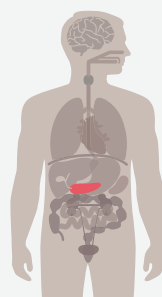
⁷van der Wiel SE, May A, Poley JW, Grubben MJAL, Wetzka J, Bruno MJ, Koch AD. Preliminary report on the safety and utility of a novel automated mechanical endoscopic tissue resection tool for endoscopic necrosectomy: a case series. *Endosc Int Open*. 2020; Mar; 8(3):E274-E280. doi: 10.1055/a-1079-5015.

⁸Bazarbashi AN, Ge PS, de Moura DTH, Thompson CC. Novel endoscopic morcellator to facilitate direct necrosectomy of solid walled-off necrosis. *Endoscopy*. 2019; Jul; 51(12):E396-E397. doi: 10.1055/a-0956-6605.

⁹Morris L, Geraghty J, Makin A. EndoRotor® use to manage walled-off pancreatic necrosis; first UK experience, *Gut*. 2019; Jun; 68(Suppl 2):A160. doi: 10.1136/gutjnl-2019-BSGAbstracts.302

¹⁰VyasN, Sachdev M, Das A, Khosravi F. Pancreatic necrosectomy using an automated mechanical endoscopic tissue extraction device. *VideoGIE*. 2018; Sep;3(11):354-355. doi: 10.1016/j.vgie.2018. 08.005.

¹¹van der Wiel SE, Poley JW, Grubben MJAL, Bruno MJ, Koch AD. The EndoRotor® , a novel tool for the endoscopic management of pancreatic necrosis. *Endoscopy*. 2018; Sep;50(9):E240-E241. doi: 10.1055/a-0628-6136.



Notes:

For more information visit www.interscopemed.com
or contact Customer Service:

USA

Tel: 800-461-4289 (toll-free in U.S.)
Email: info@interscopemed.com



Interscope, Inc.
200 Commerce Drive
Northbridge, MA 01534
USA
TEL: +1-800-461-4289
0031 (0) 73-3032541
www.interscopemed.com



EMERGO EUROPE
Prinsessegracht 20
2514 AP The Hague
The Netherlands
EMERGObyUL.com

